Heinke, Matthias; Kühnert, Helmut; Surber, Ralf; Osypka, Peter; Gerstmann, Hans; Haueisen, Jens; Heinke, Tobias; Reinhard, Dirk; Prochnau, Dirk; Dannberg, Gudrun; Figulla, Hans R.:

Termination of atrial flutter by directed transesophageal atrial pacing during transesophageal echocardiography

Zuerst erschienen in:	Biomedizinische Technik = Biomedical Engineering. - Berlin [u.a.] : de Gruyter. - 52 (2007), 2, p. 180-184.
Erstveröffentlichung:	2007-04-05
ISSN (online):	1862-278X
ISSN (print):	0013-5585
DOI:	10.1515/BMT.2007.034
[*Zuletzt gesehen:*	43696]

Biomed Tech 2007; 52:180–184 © 2007 by Walter de Gruyter • Berlin • New York. DOI 10.1515/BMT.2007.034

Termination of atrial flutter by directed transesophageal atrial pacing during transesophageal echocardiography

Terminierung von Vorhofflattern mit gerichteter transösophagealer Vorhofstimulation bei transösophagealer Echokardiographie

Matthias Heinke[1,*], Helmut Kühnert[1], Ralf Surber[1], Peter Osypka[2], Hans Gerstmann[2], Jens Haueisen[3], Tobias Heinke[3], Dirk Reinhard[1], Dirk Prochnau[1], Gudrun Dannberg[1] and Hans R. Figulla[1]

[1] Department of Internal Medicine I, Cardiology Division, Friedrich Schiller University of Jena, Jena, Germany
[2] Dr. Osypka GmbH, Rheinfelden, Germany
[3] Technical University of Ilmenau, Ilmenau, Germany

Abstract

Introduction: The purpose of this study was to evaluate termination of atrial flutter (AFL) by directed rapid transesophageal atrial pacing (TAP) with and without simultaneous transesophageal echocardiography (TEE) performed using a novel TEE tube electrode.
Materials and methods, and Results: A total of 16 AFL patients (age 63±12 years; 13 males) with mean AFL cycle length of 224±24 ms (n=12) and mean ventricular cycle length of 448±47 ms (n=12) were analyzed using either an esophageal TO electrode (n=10) or a novel TEE tube electrode consisting of a tube with four hemispherical electrodes that is pulled over the echo probe (n=6). AFL could be terminated by directed rapid TAP using an esophageal TO electrode, leading to induction of atrial fibrillation (AF) (n=6), induction of AF and spontaneous conversion to sinus rhythm (SR) (n=3), and with conversion to SR (n=1). AFL could also be terminated by directed rapid TAP using the TEE tube electrode, with induction of AF (n=3) or induction of AF and spontaneous conversion to SR (n=3).
Conclusion: AFL can be terminated by directed rapid TAP with hemispherical electrodes with and without simultaneous TEE. TAP with the directed TEE tube electrode is a safe, simple, and useful method for terminating AFL.

Keywords: atrial flutter; esophageal ECG; rapid atrial pacing; transesophageal atrial pacing; transesophageal echocardiography.

*Corresponding author: Matthias Heinke, PhD, Klinikum der Friedrich-Schiller-Universität Jena, Klinik für Innere Medizin I, Erlanger Allee 101, 07740 Jena, Germany
Phone: +49-3641-9324532
Fax: +49-3641-9324102
E-mail: matthias.heinke@med.uni-jena.de

Zusammenfassung

Einleitung: Die Terminierung von Vorhofflattern (AFL) mit gerichteter hochfrequenter transösophagealer Vorhofstimulation (TAP) wurde mit und ohne simultane transösophageale Echokardiographie (TEE) mit einer neuen TEE-Schlauchelektrode evaluiert.
Material und Methode und Ergebnisse: 16 AFL Patienten (Alter 63±12 Jahre; 13 Männer) mit einer mittleren AFL-Periodendauer von 224±24 ms (n=12) und einer mittleren ventrikulären Periodendauer von 448±47 ms (n=12) wurden mittels Ösophaguselektrode „TO“ (n=10) oder neuer „TEE-Schlauchelektrode“, die aus einem Schlauch mit 4 halbkugelförmigen Elektroden besteht und über die Echokardiographiesonde gezogen wird (n=6), analysiert. AFL konnte mit gerichteter hochfrequenter TAP und TO-Elektrode durch Induktion von Vorhofflimmern (AF) (n=6), Induktion von AF mit spontaner Konversion in den Sinusrhythmus (SR) (n=3) und Konversion in den SR (n=1) terminiert werden. AFL konnte mit gerichteter hochfrequenter TAP und TEE-Schlauchelektrode durch Induktion von AF (n=3) und Induktion von AF mit spontaner Konversion in den SR (n=3) terminiert werden.
Schlussfolgerung: AFL kann durch gerichtete hochfrequente TAP mit halbkugelförmigen Elektroden mit und ohne simultane TEE terminiert werden. TAP mit der gerichteten TEE-Schlauchelektrode ist eine sichere, einfache und praktikable Methode zur Terminierung von AFL.

Schlüsselwörter: hochfrequente Vorhofstimulation; Ösophagus-EKG; transösophageale Vorhofstimulation; Vorhofflattern.

Introduction

Transesophageal atrial pacing (TAP) for treatment of tachycardias after a transesophageal echocardiography examination is an established therapy for termination of atrial tachycardia and atrial flutter. However, simultaneous directed TAP during transesophageal echocardiography so far has not been possible [1–3, 7, 9, 12, 13]. Simultaneous transesophageal echocardiography and pacing would reduce these transesophageal procedures from two steps to one step, and thus save time and reduce patient discomfort. The purpose of this study was to compare termination of atrial flutter by directed rapid TAP with and without simultaneous transesophageal



Figure 1 Transesophageal echocardiography tube electrode (TEE electrode, Dr. Osypka GmbH) with four hemispherical electrodes and four polar adapters for combination with a transesophageal echocardiography probe, bipolar stimulator and bipolar esophageal ECG filter.
The diameter of the hemispherical electrode is 6 mm. Electrode 1 is the distal electrode and electrode 4 is the proximal electrode, with electrodes 2 and 3 between these. Bipolar transesophageal atrial pacing is possible between electrodes 1 and 3 or electrodes 4 and 2, with low-threshold pacing. Bipolar transesophageal atrial sensing is possible between electrodes 4 and 2 or electrodes 1 and 3, with high-resolution sensing. E1, distal electrode 1; E2, distal electrode 2; E3, proximal electrode 3; E4, proximal electrode 4; E1 A, adapter distal electrode 1; E2 A, adapter distal electrode 2; E3 A, adapter proximal electrode 3; E4 A, adapter proximal electrode 4.

echocardiography, using a novel transesophageal echocardiography electrode.

Materials and methods

Atrial flutter patients were analyzed using an esophageal TO electrode with one cylindrical and either three or seven hemispherical electrodes on the cardiac side of the probe (TO, Dr. Osypka GmbH, Rheinfelden, Germany) in ten patients and a transesophageal echocardiography tube electrode that is pulled over the transesophageal echocardiography probe, with four hemispherical electrodes on the cardiac side of the transesophageal echocardiography probe (TEE electrode, Dr. Osypka GmbH) in six patients (Figure 1). TAP was analyzed between different pacing dipoles. Bipolar transesophageal atrial pacing with the TEE electrode was analyzed between distal electrodes 1 and 2, electrodes 1 and 3, electrodes 4 and 2, or electrodes 1 and 4. Bipolar transesophageal atrial sensing was analyzed between proximal electrodes 4 and 3, electrodes 4 and 2, electrodes 1 and 3, or electrodes 2 and 3. Finite element simulation of the TAP electrical field was performed using Ansoft Maxwell® 2D simulation software (Figure 2), with measurement of the TAP threshold-evaluated TAP dipole of the novel TEE tube electrode for termination of atrial flutter by simultaneous transesophageal echocardiography and directed TAP [5]. The study was approved by the Ethics Committee of the Friedrich Schiller University of Jena and all patients gave informed consent.

Effective left atrial capture was possible with biphasic constant current pacing from 15 to 20 mA for a stimulus duration of 10 ms (stimulator 8817, FIAB, Florence, Italy) using the TEE electrode in six patients and for 9.9 ms (stimulator 5328, Medtronic, Inc., Minneapolis, MN, USA) with an esophageal TO electrode in ten patients. The esophageal TO electrode with one cylindrical and seven hemispherical electrodes was placed orthogonal to the coronary sinus posterior to the left atrium and to the left ventricle using the EnSite® NavX catheter navigation system (Endocardial Solutions, Inc., St. Paul, MN, USA) in one patient [6].

The electrical pacing response of transesophageal left atrial pacing during atrial flutter was analyzed on the basis of rapid bipolar TAP and bipolar filtered transesophageal atrial ECG with an esophageal TO electrode and the CardioLab® 4.1 system (Prucka Engineering, Inc., Houston, TX, USA; ten patients). TAP was analyzed in ten

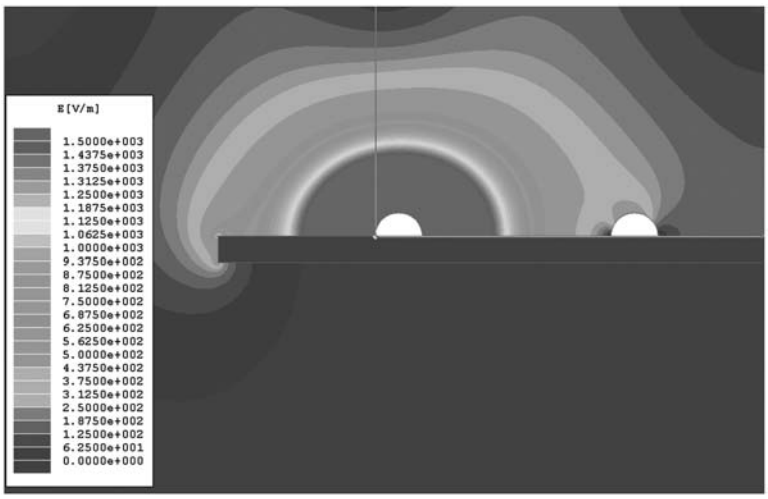

Figure 2 Finite element simulation of the directed transesophageal atrial electrical pacing field to the heart with 6-mm-diameter hemispherical electrodes (white) on the cardiac side of the probe using Ansoft Maxwell® 2D simulation software.
E indicates the amplitude of the electrical pacing field.

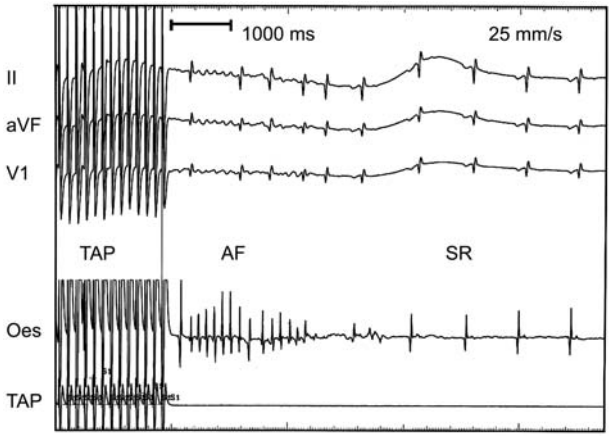

Figure 3 Rapid bipolar transesophageal atrial pacing with hemispherical electrodes in a patient with atrial flutter.
Atrial flutter was terminated by directed bipolar rapid transesophageal atrial pacing with conversion to one beat of sinus rhythm, induction of atrial fibrillation, and spontaneous conversion to sinus rhythm. Transesophageal atrial pacing and conversion to atrial fibrillation and sinus rhythm was recorded using CardioLab® 4.1 system. II, aVF, V1, surface ECG leads; Oes, bipolar filtered transesophageal atrial ECG; TAP, transesophageal atrial pacing; AF, atrial fibrillation; SR, sinus rhythm.

patients in the transesophageal electrophysiology laboratory using a transesophageal TO electrode and the Prucka CardioLab® ECG system and in six patients in the echocardiography laboratory using the TEE electrode and echocardiography system. Measurement of the atrial flutter cycle length with transesophageal atrial potential was possible in all ten patients in the transesophageal electrophysiology laboratory and in two patients in the echocardiography laboratory. Statistical analysis was performed with Origin® 7.5 (OriginLab Corporation, Northampton, MA, USA). Data are presented as mean ± SD. The t-test was used to compare TAP data. Statistical significance was defined at $p < 0.05$.

Results

Atrial flutter could be terminated by directed rapid TAP using an esophageal TO electrode after a transesophageal echocardiography examination with induction of atrial fibrillation in six patients, with induction of atrial fibrillation and spontaneous conversion to sinus rhythm in three patients, and with conversion to sinus rhythm in one patient (Figure 3). Simultaneous transesophageal echocardiography and TAP reduces two transesophageal procedures to one and thus decreases patient discomfort. Atrial flutter could be terminated by directed rapid TAP using a TEE electrode during a transesophageal echocardiography examination with induction of atrial fibrillation in three patients, and induction of atrial fibrillation and spontaneous conversion to sinus rhythm in three patients (Table 1). The mean atrial flutter cycle length was 224 ± 24 ms in 12 patients. The mean ventricular cycle length was 448 ± 47 ms in 12 patients. The mean age was 63 ± 12 years (3 females, 13 males).

Transesophageal ECG was a bipolar filtered left atrial ECG. The atrioventricular conduction relationship was 2:1 between the transesophageal left atrial and ventricular potential in 12 patients with atrial flutter. The atrioventricular conduction relationship was 3:1 or 4:1 between the transesophageal left atrial and ventricular potential in four patients with atrial flutter (Figure 4).

Bipolar TAP between two hemispherical electrodes was analyzed using a 90-mm and 60-mm TAP dipole. The capture threshold for TAP with the 60-mm dipole was lower than for the 90-mm dipole for a stimulus duration of 10 ms (15 vs. 18 ± 2.1 mA, $p = 0.02$). The minimum rapid TAP cycle length was 50 ms and the maximum stimulus output was an amplitude of 20 mA for a duration of 10 ms. The hemispherical electrical pacing field allowed directed bipolar TAP at the posterior site of the left atrium with low capture threshold and high feeling threshold (Figure 5). Bipolar TAP was possible with short and long TAP dipoles using 6-mm hemispherical elec-

Table 1 Termination of atrial flutter with transesophageal atrial pacing and different electrodes.

Patient	Age (years)	Sex	Arrhythmia	Electrode	Termination of atrial flutter with transesophageal atrial pacing to
I.K.	59	M	Atrial flutter	TO	Sinus rhythm
H.W.	47	M	Atrial flutter	TO	Atrial fibrillation and sinus rhythm
S.B.	61	M	Atrial flutter	TO	Atrial fibrillation
C.K.	60	F	Atrial flutter	TO	Atrial fibrillation
H.J.	78	F	Atrial flutter	TO	Atrial fibrillation
G.M.	68	M	Atrial flutter	TO	Atrial fibrillation and sinus rhythm
H.H.	81	M	Atrial flutter	TO	Atrial fibrillation
M.G.	57	M	Atrial flutter	TO	Atrial fibrillation
W.B.	60	M	Atrial flutter	TO	Atrial fibrillation
D.K.	69	M	Atrial flutter	TO	Atrial fibrillation and sinus rhythm
O.W.	46	M	Atrial flutter	TEE	Atrial fibrillation
M.G.	57	M	Atrial flutter	TEE	Atrial fibrillation
E.K.	63	M	Atrial flutter	TEE	Atrial fibrillation and sinus rhythm
R.L.	42	F	Atrial flutter	TEE	Atrial fibrillation and sinus rhythm
E.W.	80	M	Atrial flutter	TEE	Atrial fibrillation and sinus rhythm
W.D.	78	M	Atrial flutter	TEE	Atrial fibrillation

TO, Osypka esophageal electrode with one cylindrical and three or seven hemispherical electrodes on the cardiac side of the probe; TEE, Osypka transesophageal echocardiography tube electrode with four hemispherical electrodes that is pulled over the echo probe; M, male; F, female.

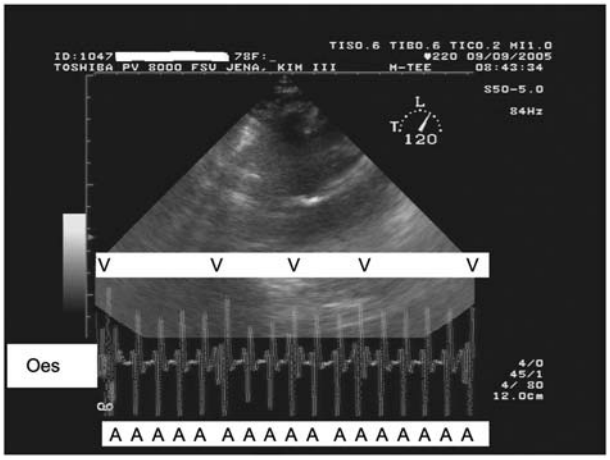

Figure 4 Simultaneous recording of bipolar filtered transesophageal atrial and ventricular ECG and transesophageal echocardiography during atrial flutter.
Transesophageal atrial and ventricular ECG was recorded between two hemispherical transesophageal echocardiography electrodes. The atrioventricular conduction relationship was 3:1 and 4:1 between the left atrial and left ventricular transesophageal potential during atrial flutter. Oes, bipolar filtered transesophageal ECG; A, transesophageal atrial potential during atrial flutter; V, transesophageal ventricular potential during atrial flutter.

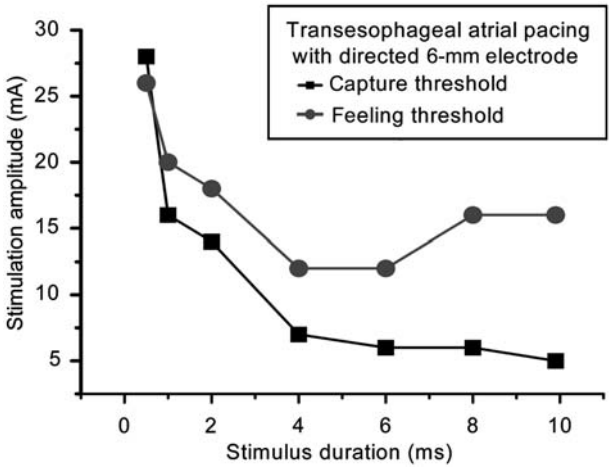

Figure 5 Low capture threshold and high feeling threshold for transesophageal atrial pacing with a directed 6-mm electrode and different stimulus duration.

trodes. The capture threshold for TAP was lower than the pain threshold in all 16 patients. Hemispherical electrodes allowed high-resolution bipolar TA sensing of the left atrial potential during atrial flutter and spontaneous rhythm after termination of atrial flutter.

Discussion

Previous studies of atrial overdrive pacing in patients with atrial flutter have demonstrated termination of atrial flutter with rapid high-threshold TAP. Termination of atrial flutter with TAP could only be achieved after, but not during, transesophageal echocardiography [8, 10, 11, 14].

This study investigated for the first time directed rapid TAP during simultaneous transesophageal echocardiography for termination of atrial flutter. The atrioventricular conduction relationship ranged from 2:1 to 4:1 between the transesophageal left atrial and left ventricular potential during atrial flutter. Atrial flutter can be terminated by directed rapid TAP with hemispherical electrodes during simultaneous transesophageal echocardiography. Termination of atrial flutter was 100%, with 57% to atrial fibrillation and 43% to sinus rhythm. There was no difference in termination of atrial flutter between the novel TEE tube electrode during simultaneous transesophageal echocardiography and the conventional transesophageal TO electrode. The capture threshold for TAP was lower than the pain threshold using the novel TEE tube electrode during simultaneous transesophageal echocardiography. Transesophageal atrial sensing and pacing was possible with short and long TEE electrode dipoles using hemispherical electrodes. The capture threshold for TAP was lower than the pain threshold using 6-mm hemispherical electrodes (9.8±3.1 vs. 10.9±5 mA for stimulus duration of 9.9 ms), but was higher than the pain threshold for TAP with 10-mm cylindrical electrodes (16.7±3.3 vs. 12.6±5.2 mA for stimulus duration of 11±3.3 ms) [4]. The application of 6-mm hemispherical electrodes allowed TAP with a low capture threshold for termination of atrial flutter. Detection of atrial flutter was possible using bipolar transesophageal atrial ECG with the novel TEE tube electrode during simultaneous transesophageal echocardiography. TAP with the directed TEE electrode is a simple and more efficient, and thus more useful method for termination of atrial flutter. Simultaneous TAP and transesophageal echocardiography reduce these procedures from two to one, and thus save time and reduce patient discomfort.

Our study shows that TAP and transesophageal atrial sensing with a directed TEE tube electrode is a simple and useful method for termination of atrial flutter. Simultaneous TAP, transesophageal atrial sensing and transesophageal echocardiography allow the treatment of atrial flutter during necessary transesophageal echocardiography examinations without an additional study.

Limitations

This was a small non-randomized study. Clinical trials are required to establish this technique for widespread use.

Acknowledgements

This study was supported in part by a grant from Dr. Osypka GmbH, Rheinfelden, Germany. The authors are grateful to Nicola Osypka, Ph.D., for manuscript revision. This study was presented in part at Cardiostim 2006, 15th World Congress in Cardiac Electrophysiology and Cardiac Techniques, Nice, France, June 14–17, 2006.

References

[1] Campbell RM, Dick M II, Jenkins JM, et al. Atrial overdrive pacing for conversion of atrial flutter in children. Pediatrics 1985; 75: 730–736.

[2] Doni F, Della Bella P, Kheir A, et al. Atrial flutter termination by overdrive transesophageal pacing and the facilitating effect of oral propafenone. Am J Cardiol 1995; 76: 1243–1246.
[3] Heinke M, Volkmann H. Balloon electrode catheter for transesophageal atrial pacing and transesophageal ECG recording. Pacing Clin Electrophysiol 1992; 15: 1953–1956.
[4] Heinke M, Kühnert H, Malur FM, Surber R, Dannberg H, Figulla HR. Transesophageal atrial pacing with different electrodes for initiation of late potential in patients after acute myocardial infarction. G Ital Cardiol 1999; 29 (Suppl 5): 438–442.
[5] Heinke M. Universell verwendbare Ösophaguselektrodensonde für transösophageale Stimulationsverfahren. Offenlegungsschrift im Deutschen Patent- und Markenamt (DPMA) DE 10 2004 001 626 A1 2005.08.18 Anmeldetag 8.1.2004, Offenlegungstag 18.8.2005, 1–7.
[6] Heinke M, Surber R, Kühnert H, Dannberg G, Schwarz G, Figulla HR. Transoesophageal left ventricular pacing in heart failure patients with permanent right ventricular pacing. Europace 2005; 7: 617–620.
[7] Kantharia BK, Mookherjee S. Clinical utility and the predictors of outcome of overdrive transesophageal atrial pacing in the treatment of atrial flutter. Am J Cardiol 1995; 76: 144–147.
[8] Lambertz H, Kreis A, Trümper H, Hanrath P. Simultaneous transesophageal atrial pacing and transesophageal two-dimensional echocardiography: A new method of stress echocardiography. J Am Coll Cardiol 1990; 16: 1143–1153.
[9] Matiouchine GV, Shulman VA, Balog AI, Bezruk AP, Golovenkin SE. Combined transesophageal left atrial pacing and antiarrhythmic therapy in the treatment of atrial flutter. Pacing Clin Electrophysiol 1996; 19: 1947–1950.
[10] McEneaney DJ. An esothoracic electrode for electrophysiological studies. J Electrocardiol 2002; 35: 151–157.
[11] Pandozi C, Scianaro MC, Magris B, et al. Transesophageal low-energy cardioversion of atrial fibrillation without fluoroscopy outside the electrophysiology laboratory. Ital Heart J 2003; 4: 335–340.
[12] Tritto M, Dicandia CD, Calabrese P. Overdrive atrial stimulation during transesophageal electrophysiological study: usefulness of post-pacing VA interval analysis in differentiating supraventricular tachycardias with 1:1 atrio-ventricular relationship. Int J Cardiol 1997; 62: 37–45.
[13] Volkmann H, Dannberg G, Heinke M, Kühnert H. Termination of tachycardias by transesophageal electrical pacing. Pacing Clin Electrophysiol 1992; 15: 1962–1966.
[14] Zardo F, Brieda M, Hrovatin E, et al. Transesophageal electrical cardioversion of persistent atrial fibrillation: a new approach for an old technology. Ital Heart J 2002; 3: 354–359.